Retinal Images: Noise Segmentation

Muhammad Usman Akram
Department of Computer Engineering
College of EME
Rawalpindi, Pakistan
usmakram@gmail.com

Anam Tariq
Department of Software Engineering
Fatima Jinnah Women University
Rawalpindi, Pakistan
anam.tariq12@gmail.com

Sarwat Nasir
Department of Computer Sciences & Engineering
Bahria University
Islamabad, Pakistan
sarwatnasir83@gmail.com

Abstract*— In automated diagnosis of Diabetic Retinopathy, retinal images are used. The retinal images of poor quality need to be enhanced before the extraction of features and abnormalities. Segmentation of retinal images is essential for this purpose. The segmentation is employed to smooth and strengthen images by separating the noisy area from the overall image thus resulting in retinal image enhancement and less processing time. In this paper, we present a novel automated approach for segmentation of colored retinal images, which involves two steps. In the first step, we create binary noise segmentation mask to segment the retinal image. Second step creates final segmentation mask by applying morphological techniques. We used standard retinal image databases Diaretdb0 and Diaretdb1 to test the validation of our segmentation technique. Experimental results indicate our approach is effective and can get higher segmentation accuracy.

Keywords-component; Diabetic retinopathy; Retinal images; Noise segmentation; Morphological operations

I. INTRODUCTION

Diabetic eye disease refers to a group of eye problems that people with diabetes may face as a complication of diabetes. Complication of diabetes, causing abnormalities in the retina and in the worst case blindness or severe vision loss, is called diabetic Retinopathy. There are no such symptoms in the early stages of diabetes but the number and severity mostly increase as the time passes. The diabetic retinopathy typically begins as small changes in the retinal capillary [1]. Hence retinal images can be used in developing tools to assist in the diagnosis of diabetic retinopathy [2].

A tool which can be used to assist in the diagnosis of diabetic retinopathy should automatically detect all retinal image features such as optic disk, fovea and blood vessel [3], [4], [5] and all abnormalities in retinal image such as microaneurysms [2], [6], [7], hard exudates and soft exudates [8], [9], hemorrhages, and edema [2].

Illumination equalization is required to enhance the image quality as the acquired color retinal images are of different qualities. Fig. 1 shows a noisy retinal image taken from standard diabetic retinopathy database diaretdb0 [10].

978-1-4244-2824-3/08/$25.00 ©2008 IEEE

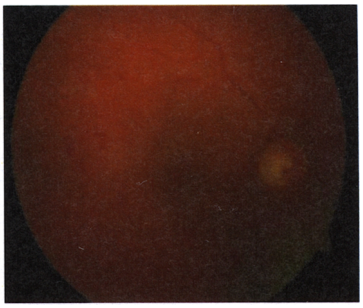

Figure 1. Noisy retinal image

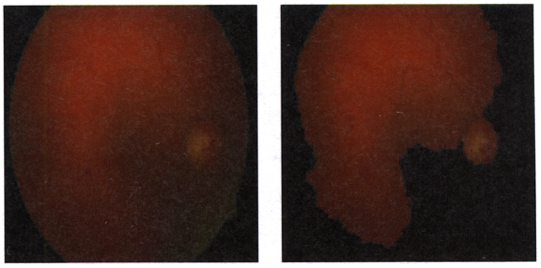

(a) (b)

Prior to the detection of retinal image features and abnormalities, segmentation of retinal image must be done for the correct diagnosis of diabetic retinopathy. The purpose of segmentation is to remove the noisy area from retinal image. It is particularly significant for the reliable extraction of features and abnormalities. Feature extraction and abnormality detection algorithms give poor results in the presence of noisy area. Fig. 2 shows the input color retinal image and the noise segmented retinal image.

Standard contrast stretching techniques have been applied by [2], [11] for segmentation and noise reduction. In [12], [13] and [14] the local contrast enhancement method is used for equalizing uneven illumination in the intensity channel of retinal images. A large mean filter, large median filter and both are used for retinal image background estimation by [9] and [15]. Wang et al. in [16] have used intensity channel

values to detect the dark regions from retinal image. In this paper, we present the retinal image segmentation technique that removes noise using HSI (Hue, Saturation, and Intensity) color space.

This paper is organized in four sections. Section II presents the step by step techniques required for color retinal image segmentation. Experimental results are discussed in section III followed by conclusion in section IV.

II. RETINAL IMAGE SEGMENTATION

Segmentation is done to extract retinal image from noisy background area. In automatic diagnosis of diabetic retinopathy, the processing of the noisy areas in retinal image is not necessary and consumes more processing time in all stages. Cutting or cropping out the region that contains the retinal image feature minimizes the number of operations on the retinal image.

Fig. 3 shows the flow diagram of our segmentation technique. It creates binary mask for noise segmentation. Then morphological operations are used on noise segmentation mask to create the final segmentation mask. Final mask is then applied to input noisy retinal image to remove the noise from it.

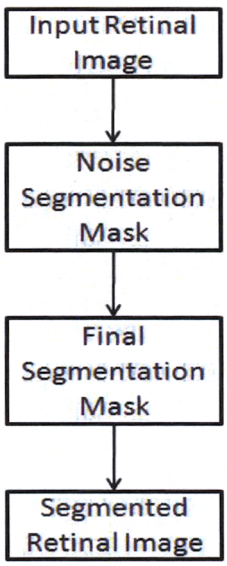

Figure 3. Flow diagram for retinal image segmentation

A. Noise Segmentation Mask

Noise in color retinal image is normally due to noise pixels and pixels whose color is distorted. Both seem to exist in regions where illumination has been inadequate. Since illumination is usually adequate in the center of the image, poor image quality regions are located near the edge of the retinal image. Regions with poor image quality may cause errors in abnormality detection. That is why they should be detected and removed before detection of abnormalities.

In our technique, we create a binary noise segmentation mask which includes the noisy area and it is applied on retinal image to ensure not to process the noisy area in upcoming steps i.e feature extraction and abnormality detection. In this segmentation technique, we convert RGB (Red, Green, Blue) retinal image into HSI (Hue, Saturation, Intensity) color space because firstly it is closer to the way a human experiences colors and secondly noise can be easily removed in HSI color space [17].

Steps for noise segmentation are summarized as follows:

- Divide the input retinal image *I(i,j)* into non-overlapping blocks with size *w x w*. In our case *w=8*.
- Use histogram equalization to enhance the contrast between background and foreground.
- Use a 3x3 median filter to reduce the noise in background of the image [17].
- Convert the equalized and filtered RGB retinal image into HSI color space using (1), (3) and (4) [17].

$$H = \begin{cases} \theta & if B \leq G \\ 360 - \theta & if B > G \end{cases} \quad (1)$$

Where

$$\theta = cos^{-1}\left\{ \frac{\frac{1}{2}[(R-G)+(R-B)]}{[(R-G)^2+(R-B)(G-B)]^{\frac{1}{2}}} \right\} \quad (2)$$

Here R, G and B represent RED, GREEN and BLUE components of RGB retinal image.

$$S = 1 - \frac{3}{(R+G+B)}[min(R,G,B)] \quad (3)$$

$$I_n = \frac{1}{3}(R+G+B) \quad (4)$$

- Calculate *N* (noise factor) due to inadequate illumination using (5).

$$N(I) = \frac{H}{I_n} \quad (5)$$

- Select a threshold value empirically working on different retinal images. If the *N (I)* is less than threshold value, the block is considered as normal retinal image area otherwise it belongs to noisy area.

Fig. 4 shows the noise segmentation. It shows the step by step output of our technique from input retinal image to binary noise segmentation mask.

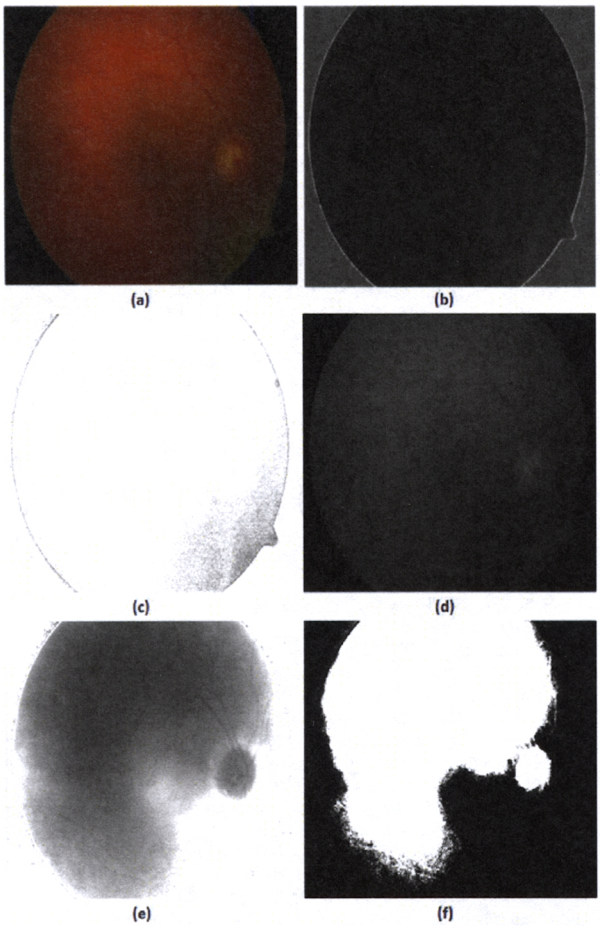

Figure 4. (a) Input Retinal Image; (b) Hue channel (H) of the original image; (c) Saturation channel (S) of the original image; (d) Intensity channel (I_n) of the original image; (e) Hue channel (H) dived by intensity channel (I_n) of the original image; (f) Result of thresholding (e).

B. Final Segmentation Mask

After doing noise segmentation, final segmentation is done by single pixel noise and edge pixels, before applying segmentation mask to retinal image. That is why,orphological operations i.e. morphological erosion and morphological dilation are applied on noise segmentation mask to create final segmentation mask.

We have used square structuring element for erosion that removes all white single pixel noise from final segmentation mask but it increases the black single pixel noise. In order to remove the black pixel noise, square structuring element, bigger in size than erosion, is used for dilation. Final noise free segmentation mask is then applied on retinal image for its segmentation. Fig. 5 shows the output of applying morphological operations and the final noise segmented retinal image.

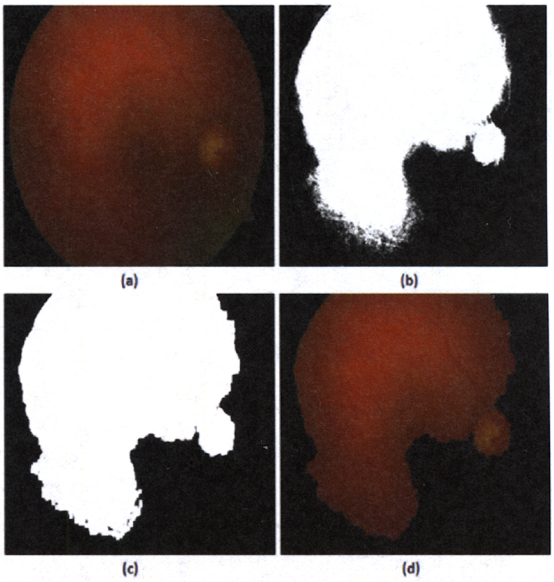

Figure 5. (a) Original retinal image; (b) Binary noise segmentation mask; (c) Final segmentation mask; (d) Noise segmented retinal image.

TABLE I. NOISE SEGMENTATION RESULTS

Masks	*Accurately segmented (Numbers)*	*Accurately segmented (%)*	*Poorly segmented (Number)*	*Poorly segmented (%)*
Noise segmentation	201	91.78	18	8.22
Final Segmentation	202	92.23	17	7.77

I. EXPERIMENTAL RESULTS

We have extensively tested our algorithms using standard diabetic retinopathy retinal image databases diarectdb0 and diaretdb1[10]. Diaretdb0 contains 130 retinal images while diaretdb1 contains 89 retinal images. These databases contain overall 219 retinal images of different qualities in terms of noise and illumination. The decision for accurate segmentation and poor segmentation is based on human eye observation. Number and percentage of accurate segmented retinal images and poorly segmented retinal images are summarized in table I. Retinal images of different illumination and noise values are shown in fig. 6.

Fig. 6 shows the noise segmentation mask, final segmentation mask and final segmented retinal image for each color retinal image. These results support the validity of our technique and show that our technique gives good results for both low and high noisy areas.

II. CONCLUSION

In this paper, color retinal images are segmented by extracting background and noise effect from the image.

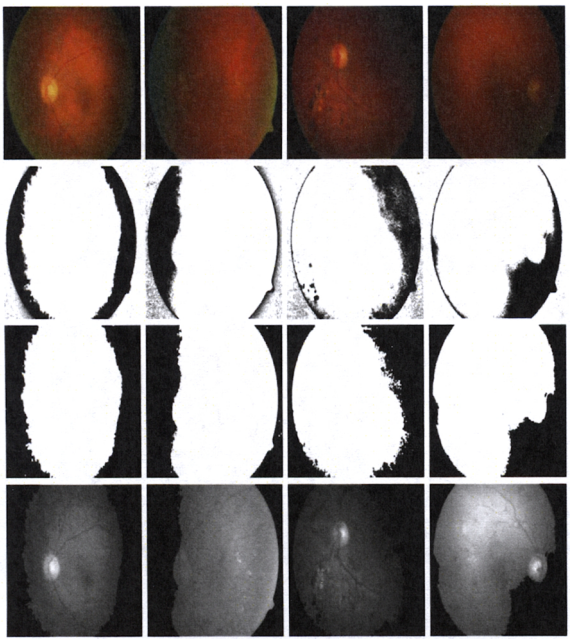

Figure 6. 1st row: Color retinal images from database, 2nd row: Noise segmentation mask, 3rd row: Final segmentation mask, 4th row: Final segmented retinal images.

Acquired retinal images must be of good quality in order to detect the abnormalities in early stages. So, it is necessary to prove the quality of retinal image. For this reason firstly noise segmentation is done and secondly morphological operations are applied on final segmentation mask to remove single pixel noise. The results are confirmed by visual inspection of segmented images taken from the standard diabetic retinopathy databases.

REFERENCES

[1] E. J. Susman, W. J. Tsiaras, and K. A. Soper, "Diagnosis of diabetic eye disease," in JAMA, vol. 247, pp. 3231-3234, 1982.

[2] S. C. Lee, E. T. Lee, R. M. Kingsley, Y.Wang, D. Russell, R. Klein, and A. Wanr, "Comparison of diagnosis of early retinal lesions of diabetic retinopathy between a computer system and human experts," in Graefes Arch. Clin. Exp. Ophtalmol., vol. 119, pp. 509-515, 2001.

[3] C. Sinthanayothin, J. F. Boyce, H. L. Cook, and T. H.Williamson, "Automated localization of the optic disc, fovea and retinal blood vessels from digital color fundus images," in Br. J. Opthalmol., vol. 83, pp. 231-238, August 1999.

[4] M. Foracchia, E. Grisan, and A. Ruggeri, "Detection of optic disc in retinal images by means of a geometrical model of vessel structure," in IEEE transactions on medical imaging, vol. 23, no.10, pp. 1189-1195, October 2004.

[5] N. k. M. N. Subhasis Chaudhuri, Shankar Chatterjee and Michael goldbaum, "Detection of blood vessels in retinal images using two-dimensional matched filters," in IEEE transactions on medical imaging, vol. 8, no. 3, pp. 263-269, 1989.

[6] T. Spencer, R. P. Phillips, P. F. Sharp, and J. V. Forrester, "Automated detection and quantification of microaneurysms in fluorescein angiograms," in Graefes Arch. Clin. Exp. Ophtalmol., vol. 230, pp. 36-41, 1991

[7] A. J. Frame, P. E. Undill, M. J. Cree, J. A. Olson, K. C. McHardy, P. F. Sharp, and J. F. Forrester, "A comparison of computer based classification methods applied to the detection of microaneurysms in ophtalmic fluorescein angiograms," in Comput. Biol. Med., vol. 28,pp. 225-238, 1998

[8] A. Osareh, M. Mirmehdi, B. Thomas, and R. Markham, "Automatic recognition of exudative maculopathy using fuzzy c-means clustering and neural networks," in Proc. Medical Image Understanding Analysis Conf., pp. 49-52, 2001.

[9] R. Phillips, J. Forrester, and P. Sharp, "Automated detection and quantification of retinal exudates," in Graefes Arch. Clin. Exp. Ophtalmol., vol. 231, pp. 90-94, 1993.

[10] Machine Vision and Pattern Recognition Research Group, "Standard diabetic retinopathy database," http://www.it.lut.fi/project/mageret/.

[11] M. H. Goldbaum, N. P. Katz, S. Chaudhuri, M. Nelson, and P. Kube, "Digital image processing for ocular fundus images," in Ophthalmol. Clin. North Amer., vol. 3, September 1990.

[12] D. Usher, M. Dumskyj, M. Himaga, T. H. Williamson, S. Nussey, and J. Boyce, "Automated detection of diabetic retinopathy in digital retinal images: a tool for diabetic retinopathy screening," in Diabetes UK. Diabetic Medicine, vol. 21, pp. 84-90, 2003.

[13] C. Sinthanayothin, V. Kongbunkiat, S. Phoojaruenchanachain, and A. Singlavanija, "Automated screening system for diabetic retinopathy," in Proceedings of the 3rd International Symposium on Image and Signal Processing and Analysis, pp. 915-920, 2003.

[14] A. Osareh, M. Mirmehdi, B. Thomas, and R. Markham, "Classification and localisation of diabetic-related eye disease," in 7th European Conference on Computer Vision, Springer LNCS 2353, pp. 502-516, 2002.

[15] N. P. Ward, S. Tomlinson, and C. J.Taylor, "Image analysis of fundus photographs," in Ophthalmology, vol. 96, pp. 80-86, 1989.

[16] H. Wang, W. Hsu, K. G. Goh, and M. L. Lee, "An effective approach to detect lesions in color retinal images," in IEEE Conference on Computer Vision and Pattern Recognition (CVPR), pp. 181-187, June 2000.

[17] R. C. Gonzalez and R. E. Woods, "Digital Image Processing," 2nd ed.Prentice Hall, 2002.