

Retinal Images: Optic Disk Localization and Detection

M. Usman Akram, Aftab Khan, Khalid Iqbal, and Wasi Haider Butt

Department of Computer Engineering,
College of Electrical & Mechanical Engineering,
National University of Sciences & Technology, Pakistan
usmakram@gmail.com, aftabkhan.nust@googlemail.com,
kiqbal@ceme.nust.edu.pk, butt.wasi@gmail.com

Abstract. Automated localization and detection of the optic disc (OD) is an essential step in the analysis of digital diabetic retinopathy systems. Accurate localization and detection of optic disc boundary is very useful in proliferative diabetic retinopathy where fragile vessels develop in the retina. In this paper, we propose an automated system for optic disk localization and detection. Our method localizes optic disk using average filter and thresholding, extracts the region of interest (ROI) containing optic disk to save time and detects the optic disk boundary using Hough transform. This method can be used in computerized analysis of retinal images, e.g., in automated screening for diabetic retinopathy. The technique is tested on publicly available DRIVE, STARE, diaretdb0 and diaretdb1 databases of manually labeled images which have been established to facilitate comparative studies on localization and detection of optic disk in retinal images. The proposed method achieves an average accuracy of 96.7% for localization and an average area under the receiver operating characteristic curve of 0.958 for optic detection.

1 Introduction

Diabetes has associated complications such as vision loss, heart failure and stroke. Patients with diabetes are more likely to develop eye problems such as cataracts and glaucoma, but the disease's affect on the retina is the main threat to vision [1]. Complication of diabetes, causing abnormalities in the retina and in the worst case severe vision loss, is called diabetic retinopathy [1].

To determine if a person suffers from diabetic retinopathy, fundus or retina image is used. Performing the mass screening of diabetes patients will result in a large number of images that need to be examined. The cost of manual examination and screening is prohibiting the implementation of screening on a large scale. A possible solution could be the development of an automated screening system for diabetic retinopathy [2]. Such a system should be able to distinguish between affected eye and normal eye. This will significantly reduce the workload for the ophthalmologists as they have to examine only those images classified as possibly abnormal by the system. Accurate optic disk localization

and detection of its boundary is main and basic step for automated diagnosis systems [3]. OD is a bright yellowish disk in human retina from where the blood vessels and optic nerves emerge [1].

Figure 1 shows a healthy retinal image including main retinal features i.e. optic disk, blood vessels and macula. The shape, color and size of optic disk help in localization and detection. However, these properties show a large variance

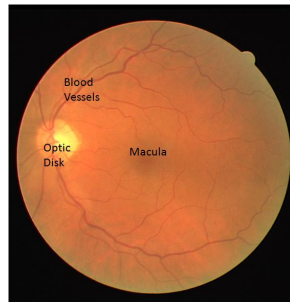


Fig. 1. Healthy retinal image with features

Figure 2 shows examples of a swollen optic nerve, where the circular shape and size are distorted. It also shows an example with a bright circular lesion that appears similar to optic disk.

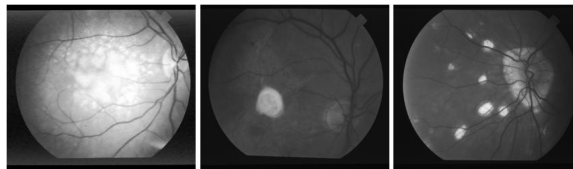


Fig. 2. Retinal images with lesions and distorted shape of optic disk

Localizing the centre and rim of the optic disk is necessary to differentiate the optic disk from other features of the retina and as an important landmark. Techniques described in the literature for optic disk localization are typically aimed at either identifying the approximate centre of the optic disk or placing the disk within a specific region such as a circle or square. In [4], an approximate location of the optic disk is estimated where the location of the optic disk is hypothesized by searching for regions of high intensity, diversity of gradient directions, and convergence of blood vessels. Sinthanayothin [5] located the position of the optic disk by finding the region with the highest local variation in the intensity. Hoover [6] utilized the geometric relationship between the optic disk and main blood vessels to identify the disk location. He described a method based on a fuzzy voting mechanism to find the optic disc location. Mendels et al. [7] and

Osareh et al. [8] introduced a method for the disk boundary identification using free-form deformable model technique. Li and Chutatape [9][10] used a PCA method to locate the optic disk and a modified active shape model (ASM) to refine the optic disk boundary based on point distribution model (PDM) from the training sets. A method based on pyramidal decomposition and Hausdorff distance based template matching was proposed by Lalonde et al. [11].

In this paper, we propose a Hough Transformation based technique for OD localization and detection. In our proposed method, firstly, optic disk localization is done by averaging and then detecting the maximum gray values from an image histogram. Secondly, ROI is extracted and optic disk detection is done by taking Circular Hough Transform of an image which is followed by clinical validation of our Hough based technique. We test the validity of our method on four different publicly available databases i.e DRIVE [12], STARE [13], diaretdb0 and diaretdb1 [14].

This paper is organized in four sections. In Section 2, systematic overview of our methodology is explained. Section 2 also presents the step by step techniques required for an automated optic disk localization and detection system. Experimental results of the tests on the images of the different databases and their analysis are given in Section 3 followed by conclusion in Section 4.

2 System Overview

A systematic overview of the proposed technique is shown in figure 3. In summary, given a pair of color retinal images, the first step localizes the optic disk, the second step extracts ROI and in the third step optic disk detection takes place. The results are utilized for clinical validation of optic disk detected images.

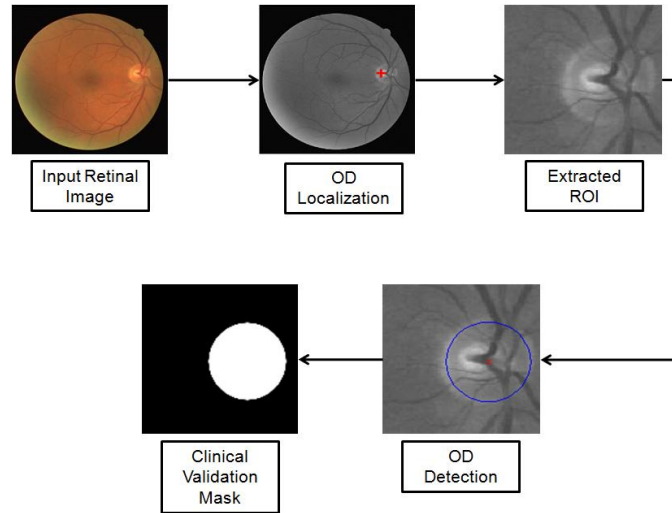


Fig. 3. Retinal images with lesions and distorted shape of optic disk

2.1 Optic Disk Localization

Localization of the optic disc is the first step in our technique. The purpose of localization is to have low processing rate and less computational cost in further steps. Steps for OD detection are as follows:

1. Image is preprocessed by averaging mask of size 31x31, given in eq. 1, in order to remove the background artifacts which can cause false localization.

$$R = \frac{1}{961} \sum_{i=1}^{961} Z_i \quad (1)$$

where z 's are values of image gray levels and R is the smoothed image.

2. Detect maximum gray values in an image histogram because the gray values of optic disc are brighter than the background values.

Figure 4 shows the images after applying above steps.

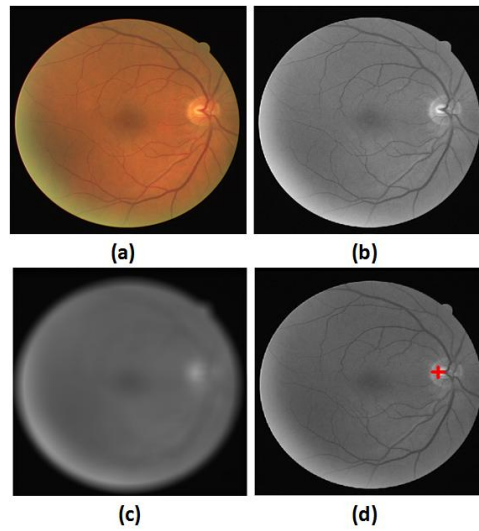


Fig. 4. Optic disk localization: (a) Original retinal image from DRIVE database; (b) Green channel image; (c) Averaged image; (d) Localized optic disk

2.2 Optic Disk Detection

After localizing the optic disc we have to define the region of interest (ROI) for increasing the performance of optic disc detection. After smoothing the size of ROI was set to 130 x 130. After extraction of ROI, we have to detect the optic disc boundary using Hough Transform [15]. The Hough Transform is used to identify the locations and orientations of retinal image features. This transform consists

of parameterized description of a feature at any given location in the original image space. It can be used for representing objects that can be parameterized mathematically as in our case, a circle, can be parameterized by equation 2.

$$(x - a)^2 + (y - b)^2 = r^2 \quad (2)$$

Where (a,b) is the coordinate of center of the circle that passes through (x,y) and r is its radius. From this equation, it can be seen that three parameters are used to formalize a circle which means that Hough space will be 3D space for this case. The steps for detecting optic disc boundary by Hough Transform are below:

Edge Detection. In order to calculate the Hough Transform, the edge of the OD's circular shape is needed. Canny Edge detection operator is applied to the image as a first step in this process. This removes most of the noise due to its fine texture leaving only the required edges of the OD. Experimentally, we found that the Canny Operator with the parameters $\sigma = 1$ and window size 5×5 gives best results.

First Approximation of Optic Disc. For the rough calculation of OD in this step, the accumulator parameter array is filled where each array is composed of cells for (x,y) coordinates of the center of circle. The edge image is scanned and all the points in this space are mapped to Hough space using equation (2). A value in particular point in Hough space is accumulated if there is a corresponding point in the retinal image space. The process is repeated until all the points in the retinal image space are processed. The resulting Hough transform image was scaled so all the values lie between 0 and 1. Then it was threshold to leave only those points with high probability of being the centers which are then labeled with different numbers. Afterwards the different regions were matched by different circles and the output image is computed by drawing circle with these points and adding this to the input image.

Detecting Best Circle. In this step, the set of approximated circles from step 2 will be compared. The best circle of this set would be that one that fits most of the OD edges. In this step, numbers of pixels which are in the vicinity of detected circle's edge are counted. A mask of a ring shaped is put on the binary edge image on the same location of each of the detected circle. Number of edge pixels under this mask will be counted and compared for all the detected circles. The best circle shows the location of the detected optic disc.

The results were also clinically validated. All images in our test set are sent to ophthalmologist to identify the OD manually. All the OD's which are automatically detected by our system are then compared with clinician's hand-drawn ground truth. Figure 5(d) and 5(e) shows an example of our detected optic disk and manually segmented mask by ophthalmologist respectively.

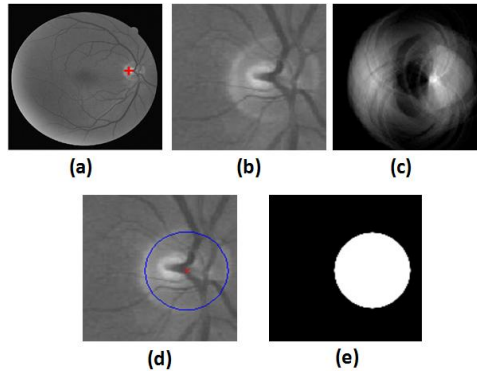


Fig. 5. Optic disk detection: (a) Localized optic disk; (b) Extracted ROI; (c) Hough transform circles; (d) Detected optic disk; (e) Manually segmented mask for clinical validation

3 Experimental Results

We have extensively tested our optic disk localization and detection technique on standard diabetic retinopathy databases. We have used four publicly available datasets, DRIVE, STARE, diaretdb0 and diaretdb1. The DRIVE [12] database consists of 40 RGB color images of the retina. The images are of size 768584 pixels, eight bits per color channel. The STARE [13] database consists of 20 RGB color images of the retina. The images are of size 605700 pixels, 24 bits per pixel (standard RGB). Diaretdb0 [14] database contains 130 retinal images while diaretdb1 [14] database contains 89 retinal images. These databases contain retinal images with a resolution of 1500 x 1152 pixels and of different qualities in terms of noise and illumination. The decision for successful localization or failed localization is based on human eye observation. For the verification of optic disk detection results, optic disks are manually labeled by the ophthalmologists for each image. The manually segmented optic disks by human observer are used as ground truth. The true positive fraction is the fraction of number of true positive (pixels that actually belong to optic disk) and total number of optic disk pixels in the retinal image. False positive fraction is calculated by dividing false positives (pixels that don't belong to optic disk) by total number of non optic disk pixels in the retinal image. Table 1 summarizes the results of optic disk localization for all four databases. It shows the accuracy (fraction of successful localized OD) of proposed algorithm for each database. Table 2 summarizes the results of optic disk detection for all databases. It shows the results in term of A_z , average accuracy and their standard deviation for different datasets. A_z indicates the area under the receiver operation characteristics curve and accuracy is the fraction of pixels correctly detected.

Figure 6 illustrates the optic disk localization results for retinal images taken from different databases. Red cross sign shows the optic disk location in each

Table 1. Optic disk localization results

Database	Total images	Successful localization	Failed localization	Accuracy (%)
DRIVE	40	40	0	100
STARE	81	76	5	93.8
Diarectdb0	130	126	4	96.9
Diarectdb1	89	87	2	97.7
Overall	340	329	11	96.7

Table 2. Optic disk detection results

Database	Az	Average Accuracy
DRIVE	0.971	0.955
STARE	0.943	0.921
Diarectdb0	0.957	0.932
Diarectdb1	0.961	0.937
Overall	0.958	0.936

Table 3. Comparison Results for OD localization

Method	Total images	Successful localization	Failed localization	Accuracy (%)
Hoover et al.	81	72	9	88.8
Proposed Method	81	76	5	93.8

image. These results support the validity of our technique and show that our technique gives good results for localization even for those images where it is difficult to locate optic disk. Figure 7 compares the results of proposed OD localization technique against Hoover et al. [6] localization method. It shows the successful localization results for our method.

Our method achieved an accuracy of 93.8% against 88.8% achieved by Hoover et al.[6] and is summarized in table 3.

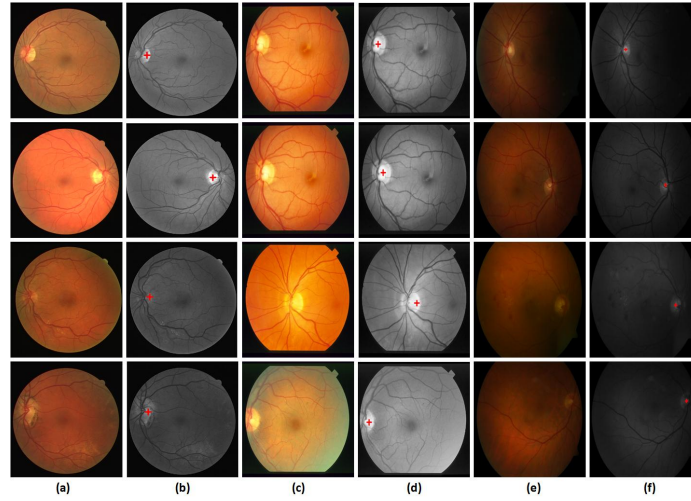


Fig. 6. Experimental results: (a) Retinal images from DRIVE database; (b) Optic disk localization results; (c) Retinal images from STARE database; (d) Optic disk localization results; (e) Retinal images from Diarectdb0 and Diarectdb1 database; (f) Optic disk localization results

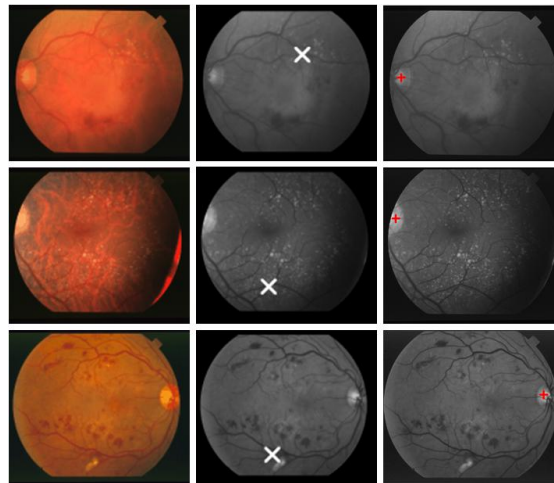


Fig. 7. Comparison results: Column 1: Original retinal images from STARE database, Column 2: Wrongly localized optic disks using Hoover et al [6] method, Column 3: Correctly localized optic disks using proposed method

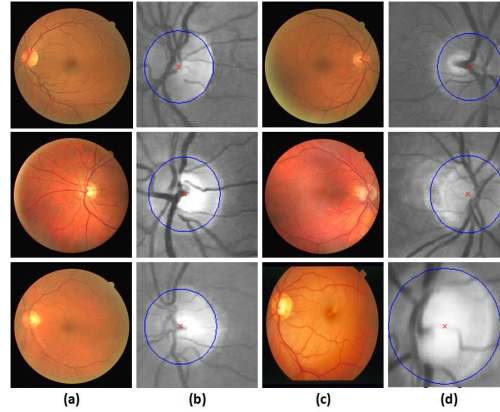


Fig. 8. Experimental results for optic disk detection: Column (a) and (c) Retinal images from different databases; Column (b) and (d) Optic disk detection results

Figure 8 shows the optic disk detection results based on Hough transform. Red cross shows the centroid of optic disk where as blue boundary encloses the optic disk.

4 Conclusion

Our proposed approach for automated optic disk localization and detection is effective in handling retinal images under various conditions with reasonable accuracy and reliability for medical diagnosis. The problem with retinal images is that the visibility and detection of optic disk are usually not easy especially in presence of some lesions. In this paper, retinal images are preprocessed and ROI is extracted prior to optic disk detection. Optic disk is localized using average masking and histogram and it is detected using Hough transform. We have tested our technique on publicly available DRIVE, STARE, diaretdb0 and diaretdb1 databases of manually labeled images. The experimental results demonstrated that our method performs well in locating and detecting optic disk.

References

1. Susman, E.J., Tsiaras, W.J., Soper, K.A.: Diagnosis of diabetic eye disease. *JAMA* 247(23), 3231–3234 (1982)
2. Effective Health Care - Complications of diabetes: Screening for retinopathy and Management of foot ulcers., vol. 5(4). Royal Society of Medicine Press (1999) ISSN 0965-0288
3. Osareh, A., Mirmehdi, M., Thomas, B., Markham, R.: Automated Identification of Diabetic Retinal Exudates in Digital Colour Images. *British Journal of Ophthalmology* 87(10), 1220–1223 (2003)

4. Narasimha-Iyer, H., Can, A., Roysam, B., Stewart, C.V., Tanenbaum, H.L., Majerovics, A., Singh, H.: Robust Detection and Classification of Longitudinal Changes in Color Retinal Fundus Images for Monitoring Diabetic Retinopathy. *IEEE transactions on biomedical engineering* 53(6), 1084–1098 (2006)
5. Sinthanayothin, C., Boyce, J.A., Cook, H.L., Williamson, T.H.: Automated localisation of the optic disc, fovea, and retinal blood vessels from digital colour fundus images. *British Journal of Ophthalmology* 83, 902–910 (1999)
6. Hoover, A., Goldbaum, M.: Locating the optic nerve in a retinal image using the fuzzy convergence of the blood vessels. *IEEE Trans. on Medical Imaging* 22(8), 951–958 (2003)
7. Mendels, F., Heneghan, C., Thiran, J.P.: Identification of the optic disc boundary in retinal images using active contours. In: *Proc. IMVIP conference*, pp. 103–115 (1999)
8. Osareh, A., Mirmehd, M., Thomas, B., Markham, R.: Comparison of colour spaces for optic disc localisation in retinal images. In: *16th International Conference on Pattern Recognition*, vol. 1, pp. 743–746 (2002)
9. Li, H., Chutatape, O.: Automated feature extraction in color retinal images by a model based approach. *IEEE Trans. on Biomedical Engineering* 51(2), 246–254 (2004)
10. Li, H., Chutatape, O.: Boundary detection of optic disk by a modified ASM method. *Pattern Recognition* 36(9), 2093–2104 (2003)
11. Lalonde, M., Beaulieu, M., Gagnon, L.: Fast and robust optic disc detection using pyramidal decomposition and Hausdorff-based template matching. *IEEE Trans. Med. Imag.* 20(11), 1193–2001 (2001)
12. Niemeijer, van Ginneken, B.: (2002), <http://www.isi.uu.nl/Research/Databases/DRIVE/results.php>
13. Hoover, STARE database, <http://www.ces.clemson.edu/ahover/stare>
14. Machine Vision and Pattern Recognition Research Group, Standard diabetic retinopathy database, <http://www.it.lut.fi/project/imageret/>
15. Sekhar, S., Al-Nuaimy, W., Nandi, A.K.: Automated localisation of retinal optic disk using Hough transform. In: *5th IEEE International Symposium on Biomedical Imaging: From Nano to Macro*, pp. 1577–1580 (2008)